Check for updates

Histopathology

Histopathology 2018, **72**, 1075–1083. DOI: 10.1111/his.13446

REVIEW

Invasion in breast lesions: the role of the epithelial–stroma barrier

Emad A Rakha,[1] Islam M Miligy,[1] Kylie L Gorringe,[2,3] Michael S Toss,[1] Andrew R Green,[1] Stephen B Fox,[4] Fernando C Schmitt,[5] Puay-Hoon Tan,[6] Gary M Tse,[7] Sunil Badve,[8] Thomas Decker,[9] Anne Vincent-Salomon,[10] David J Dabbs,[11] Maria P Foschini,[12] Filipa Moreno,[13] Yang Wentao,[14] Felipe C Geyer,[15] Jorge S Reis-Filho,[15] Sarah E Pinder,[16] Sunil R Lakhani[17] & Ian O Ellis[1]

[1]*Department of Histopathology, Nottingham City Hospital NHS Trust, Nottingham University, Nottingham, UK,* [2]*Cancer Genomics Program, Peter MacCallum Cancer Centre, Melbourne, Vic., Australia,* [3]*The Sir Peter MacCallum Department of Oncology, University of Melbourne, Melbourne, Vic., Australia,* [4]*Pathology Department, Peter MacCallum Cancer Centre, Melbourne, Vic., Australia,* [5]*Institute of Molecular Pathology and Immunology (IPATIMUP) and Medical Faculty, University of Porto, Porto, Portugal,* [6]*Department of Pathology, Singapore General Hospital, Singapore,* [7]*Department of Anatomical and Cellular Pathology, Prince of Wales Hospital, Hong Kong,* [8]*Departments of Pathology and Internal Medicine, Clarian Pathology Laboratory of Indiana University, Indianapolis, IN, USA,* [9]*Breast-Screening-Pathology, Reference Centre Munster, Gerhard Domagk-Institute of Pathology, University Hospital Münster, Münster, Germany,* [10]*Department of Pathology, Institute Curie, PSL Research University, Paris, France,* [11]*University of Pittsburgh Medical Centre, Pittsburgh, PA, USA,* [12]*Department of Biomedical and Neuromotor Sciences, Section of Anatomic Pathology at Bellaria Hospital, University of Bologna, Bologna, Italy,* [13]*Anatomic Pathology Department, Centro Hospitalar do Porto, Porto, Portugal,* [14]*Pathology, Fudan University Shanghai Cancer Center, Shanghai, China,* [15]*Department of Pathology, Memorial Sloan Kettering Cancer Centre, New York, NY, USA,* [16]*Division of Cancer Studies, King's College London, Guy's Hospital, London, UK, and* [17]*Discipline of Molecular & Cellular Pathology, Faculty of Medicine, University of Queensland, The Royal Brisbane & Women's Hospital, Brisbane, QLD, Australia*

Rakha E A, Miligy I M, Gorringe K L, Toss M S, Green A R, Fox S B, Schmitt F C, Tan P-H, Tse G M, Badve S, Decker T, Vincent-Salomon A, Dabbs D J, Foschini M P, Moreno F, Wentao Y, Geyer F C, Reis-Filho J S, Pinder S E, Lakhani S R & Ellis I O

(2018) *Histopathology* **72**, 1075–1083. https://doi.org/10.1111/his.13446

Invasion in breast lesions: the role of the epithelial–stroma barrier

Despite the significant biological, behavioural and management differences between ductal carcinoma *in situ* (DCIS) and invasive carcinoma of the breast, they share many morphological and molecular similarities. Differentiation of these two different lesions in breast pathological diagnosis is based typically on the presence of an intact barrier between the malignant epithelial cells and stroma; namely, the myoepithelial cell (MEC) layer and surrounding basement membrane (BM). Despite being robust diagnostic criteria, the identification of MECs and BM to differentiate *in-situ* from invasive carcinoma is not always straightforward. The MEC layer around DCIS may be interrupted and/or show an altered immunoprofile. MECs may be absent in some benign locally infiltrative lesions such as microglandular adenosis and infiltrating epitheliosis, and occasionally in non-infiltrative conditions such as apocrine lesions, and in these contexts this does not denote malignancy or invasive disease with metastatic potential. MECs may

Address for correspondence: E A Rakha, Department of Histopathology, Nottingham University Hospital NHS Trust, City Hospital Campus, Hucknall Road, Nottingham NG5 1PB, UK. e-mail: emad.rakha@nottingham.ac.uk; emad.rakha@nuh.nhs.uk

[Correction added on 26 February 2018, after first online publication: The surname of the 15th author was corrected to Moreno.]

© 2017 John Wiley & Sons Ltd.

also be absent around some malignant lesions such as some forms of papillary carcinoma, yet these behave in an indolent fashion akin to some DCIS. In Paget's disease, malignant mammary epithelial cells extend anteriorly from the ducts to infiltrate the epidermis of the nipple but do not typically infiltrate through the BM into the dermis. Conversely, BM-like material can be seen around invasive carcinoma cells and around metastatic tumour cell deposits. Here, we review the role of MECs and BM in breast pathology and highlight potential clinical implications. We advise caution in interpretation of MEC features in breast pathology and mindfulness of the substantive evidence base in the literature associated with behaviour and clinical outcome of lesions classified as benign on conventional morphological examination before changing classification to an invasive lesion on the sole basis of MEC characteristics.

Keywords: basement membrane, breast cancer, ductal carcinoma *in situ*, microenvironment, myoepithelial cells

Introduction

Ductal carcinoma *in situ* (DCIS) of the breast is defined as a proliferation of malignant epithelial cells confined to the ducto-lobular system of the breast without evidence of stromal invasion.[1,2] Invasion is defined morphologically, as in other organ sites, by the absence, or breaching, of the basement membrane (BM) barrier between the malignant epithelial cells and surrounding stroma. In the breast there is an additional myoepithelial cell (MEC) layer between the epithelium and the BM. At the molecular level, DCIS progresses to invasive carcinoma when malignant cells acquire the invasive phenotype[1,3] that has the capability to infiltrate through both the MEC and BM layers. Because of challenges and limitations in identifying BM components using immunocytochemistry (IHC), the MEC layer has gained importance because of the greater simplicity of its identification immunohistochemically and is thus used as a surrogate marker for invasion through the BM. The loss of the MEC layer in breast pathology has become a key criterion for differentiating non-invasive from invasive disease implying, possibly incorrectly in some contexts, direct exposure of the malignant epithelial cells to the stroma and a subsequent ability to infiltrate and metastasise.

Understanding the events that lead to invasiveness and the role of MECs and BM is crucial in improving diagnosis and management of various breast lesions. This review addresses the features and roles of MECs and BM in the understanding and diagnosis of breast lesions with an emphasis on DCIS, and highlights the morphological use of specific features for differentiating benign from malignant lesions and *in situ* from invasive disease that have significant management implications.

Features of DCIS progression to invasive carcinoma

During progression from *in-situ* to invasive disease interactions between intraductal malignant cells and peripheral MECs, which are thought to act as a 'gatekeeper' exerting tumour-suppressive effects,[4] take place leading to loss of MECs unleashing the progression to invasive disease.[5,6] Molecular studies of DCIS and invasive breast cancer (IBC) suggest that this progression is driven not only by genomic aberrations in the malignant cells but also a result of complex processes involving interactions and cross-talks of tumour cells with the surrounding stromal environment including BM, stromal cells, vascular spaces and immune cells[7–9] (Figure 1). In fact, the process of progression to invasive disease is multifactorial and complex. It is thought that the activity of proteolytic proteins secreted by the malignant cells to breach the BM and surrounding stroma is sufficient to explain progression[9]; however, results of clinical trials of inhibitors of proteolytic enzymes to suppress tumour progression have not been promising.[10] In view of the limited success in identifying genetic aberrations in the malignant cells of DCIS that can predict invasion, despite all previous efforts we believe that further understanding of the role of the microenvironment and its interaction with DCIS cells may help in deciphering this complex process of invasion with the potential of improving patient management.

Characterisation of DCIS-associated myoepithelial cells

Myoepithelial cells surround both normal terminal duct lobular units and larger ducts as well as precancerous (*in-situ*) lesions of the breast, forming a

13652559, 2018, 7, Downloaded from https://onlinelibrary.wiley.com/doi/10.1111/his.13446 by George Mason University, Wiley Online Library on [10/03/2026]. See the Terms and Conditions (https://onlinelibrary.wiley.com/terms-and-conditions) on Wiley Online Library for rules of use; OA articles are governed by the applicable Creative Commons License

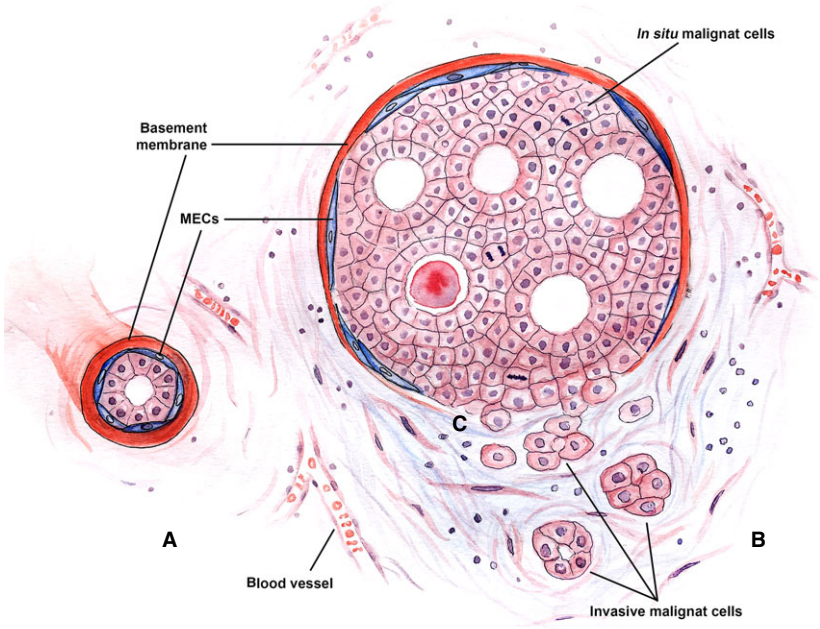

Figure 1. Schematic representation of normal breast terminal duct (**A**) and ductal carcinoma *in situ* (DCIS) with focus of early invasion (**B**). Normal ducts (**A**) present with continuous myoepithelial cell (MEC) layer (**B**) and surrounding continuous well-defined basement membrane (**A**). Although MECs surround both normal ducts and malignant *in-situ* lesions, MECs surrounding DCIS show some morphological differences and lose the power to polarise epithelial cells. Changes in MEC layer continuity might be related to mechanical factors, immune reaction, loss of cellular renewal capacity or exogenous chemical influence. Stromal invasion and progression to invasive disease (**C**) starts with breaching, or absence, of MEC layer and basement membrane barriers between the malignant epithelial cells and surrounding stroma. Changes in the interaction between malignant epithelial cells and stromal microenvironment, including the extracellular matrix, fibroblasts and immune cells, are believed to also play a role in invasion.

natural barrier and in the latter situation separating the abnormally proliferating epithelial (luminal) cells from the surrounding various stromal elements. It has been postulated that disruption of this barrier is required for tumour invasion and metastasis.[11]

LOSS OF PHYSICAL BARRIER

Myoepithelial cells surrounding DCIS show some morphological differences to normal breast MECs, and there is evidence to indicate that DCIS-derived MECs lose the power to polarise luminal epithelial cells.[12] Interestingly, discontinuity in expression of MEC markers in the absence of microinvasion of tumour cells into the surrounding stroma has been observed, raising the possibility that this could be the primary event which precedes tumour invasion.[13] Such interruption in the MEC layer integrity may be due to mechanical factors, immune reaction or loss of cellular renewal capacity.[11] The loss of tumour suppressor control on the epithelial cells facing these interrupted MECs has been supported through the analysis of the genetic and IHC features of cell clusters overlying focally disrupted MECs.[9,11]

TUMOUR SUPPRESSOR FUNCTION

Myoepithelial cells have natural tumour suppressor functions, including maintenance of the BM and epithelial cell polarity,[14] and express several tumour suppressor proteins such as p63, p73, 14-3-3 sigma, maspin, Wilms tumour 1 (WT1) and laminin 1. MECs also exhibit many other anti-tumorigenic properties, such as inhibition of the growth of breast cancer cells by inducing a G2/M cell cycle arrest, inhibiting tumour cell invasion and lowering angiogenesis by paracrine control.[15,16] Evolving experimental evidence indicates that their tumour-suppressive phenotype may be achieved partly by secreting protease inhibitors and down-regulating matrix metalloproteinases.[4] MECs also express several extracellular matrix (ECM) structural proteins and accumulate ECM rather than degrade it.[17] MECs participate in BM production by expression and deposition of

13652559, 2018, 7, Downloaded from https://onlinelibrary.wiley.com/doi/10.1111/his.13446 by George Mason University, Wiley Online Library on [10/03/2026]. See the Terms and Conditions (https://onlinelibrary.wiley.com/terms-and-conditions) on Wiley Online Library for rules of use; OA articles are governed by the applicable Creative Commons License

fibronectin, collagen IV and laminins. They also have BM receptors, including integrins, which mediate cell–BM attachment and occasionally cell-to-cell interactions.[18]

At the molecular level, it has been shown that DCIS-associated MECs have molecular, genetic and epigenetic differences from MECs in normal breast tissue.[19,20] These changes include down-regulation of genes that control normal MEC functions and up-regulation of genes for chemokines that enhance epithelial cell proliferation, migration and invasion.[21,22] Allinen and colleagues examined the microenvironment of normal and cancerous breast tissue and found that MECs in association with DCIS lesions exhibited the most abundant gene expression changes of all the microenvironmental cell types,[20] although the predictive and functional relevance of these changes *per se* are not certain. Other authors have identified specific differences in gene expression between normal and DCIS-associated MECs, such as increased lysyl oxidase[23] and neuropillin 1.[24]

It has been noted that the sensitivity of some MEC markers is lower in DCIS-associated MECs than in normal MECs, and this observation should be taken into consideration when selecting MEC markers to distinguish *in situ* from IBC.[21] A summary of biomarkers used to visualise MECs in routine diagnostic practice are included in Table 1.

Calponin, for instance, is an integral component of α-smooth muscle actin (SMA), and its down-regulation is consistent with compromised MECs. Maspin, which is one of the most important tumour suppressors secreted by MECs,[25] is secreted in large quantities by the normal MECs, while DCIS-associated MECs do not secrete it.[25] MECs secrete laminin 1, which is a major component of the BM structure and plays a crucial role in the polarity of epithelial cells within the ducts. MECs associated with DCIS show deficient laminin 1 deposition and hence loss of cellular polarity and differentiation facilitating tumour invasion.[12,17] MECs surrounding malignant cells also express elevated integrin αvβ6, which has been shown to promote tumour proliferation and invasion.[26]

Myoepithelial cells isolated from DCIS have been reported to show gene expression and epigenetic changes when compared to MECs isolated from normal breast tissue,[19,20] but no study has been able to demonstrate significant differences between MEC marker expression in DCIS with or without associated invasive carcinoma. Exploring such differences is clearly clinically important due to their potential as biomarkers of invasive progression.

Observed effects of lack of MECs on epithelial proliferative breast lesions

Despite the documented role of MECs in the progression of DCIS to invasive disease and the application of MEC IHC marker by pathologists to differentiate *in situ* from invasive tumours in routine practice, well-known exceptions exist and potentially challenge this dogma which, if not recognised, can lead potentially to incorrect classification of a condition as an invasive carcinoma. The biologically unexplained phenomenon of the absence of peripheral MEC in lesions regarded conventionally as non-invasive, or even non-neoplastic, is observed uncommonly in breast histopathology (Table 2). Microglandular adenosis (MGA) and the rare entity of so-called 'infiltrating epitheliosis' are two examples of non-malignant breast lesions that lack peripheral MECs.[27–30]

Microglandular adenosis shows infiltrating single-layer glands surrounded by a distinct well-developed layer of BM but lack a MEC layer. Cells of MGA show an immunophenotype that is different from hyperplastic epithelial cells in other breast lesions; they lack oestrogen receptor expression and show diffuse nuclear staining of S100 protein. Shared clonal driver mutations between uncommon cases with MGA and synchronous invasive carcinoma, suggestive of a precursor relationship, have been reported.[31,32] Although atypia and carcinoma can arise from MGA, no metastasis has been reported in cases of pure MGA, which is the unequivocal hallmark and key clinical relevance of invasive disease. However, the absence of peripheral MECs poses a diagnostic challenge when the proliferating cells also show cytonuclear atypia, and it can be extremely difficult to differentiate atypical MGA from invasive carcinoma. In addition, the infiltrative nature and morphology of MGA suggests that its BM is produced by the proliferating cells, rather than being a native BM.

Infiltrating epitheliosis is another example of a benign epithelial lesion that shows an infiltrative growth pattern with focal absence of MECs. This lesion, described originally by Azzopardi, is described using his original criteria as a lesion that mimics carcinoma.[33] It is considered to be related to radial scar/complex sclerosing lesions[33] and sometimes with sclerosed papillary lesions.[34] MECs are mainly lost at the periphery of an infiltrative epitheliosis lesion, with frequent preservation at the epithelial–stroma interface in the centre. Interestingly, MECs may be demonstrated in the proximal part of a duct but completely absent at the distal part where the infiltrative pattern becomes more obvious. Unlike MGA, in infiltrating

13652559, 2018, 7, Downloaded from https://onlinelibrary.wiley.com/doi/10.1111/his.13446 by George Mason University, Wiley Online Library on [10/03/2026]. See the Terms and Conditions (https://onlinelibrary.wiley.com/terms-and-conditions) on Wiley Online Library for rules of use; OA articles are governed by the applicable Creative Commons License

Table 1. Immunohistochemical markers used for detection of myoepithelial cells and basement membrane in breast pathology

MECs markers	Sensitivity	Specificity	Localisation	Comments
Smooth muscle actin (SMA)	High	Low	Cytoplasmic	Any cell with substantial expression of actin is positive for SMA (myofibroblasts and blood vessels)
Smooth muscle myosin heavy chain (SMMHC)	Good	Good	Cytoplasmic	Less sensitive than SMA, but more specific and easy to interpret
P63	High	High	Nuclear	Focal gaps in staining in MEC layer. Around 5–10% of invasive tumours, particularly high-grade, metaplastic and salivary-like carcinomas, express p63
Calponin	High	Low	Cytoplasmic	Present in a subset of myofibroblasts and smooth muscle in blood vessels
H-caldesmon	Good	Good	Cytoplasmic	MEC around ducts and lobules may not express H-caldesmon
Maspin	Good	Good	Cytoplasmic, nuclear	Some invasive carcinomas have been reported as showing maspin expression
CD10	Good	Good	Cytoplasmic	Rarely expressed in the tumour cells of invasive carcinomas and in some sarcomas. Less sensitive than SMA
Basal CKs (CK5/6, CK14, CK17)	Low	Low	Cytoplasmic, membranous	Low sensitivity and specificity. Positive in carcinomas, particularly high-grade lesions
p-cadherin	Good	Good	Cytoplasmic	No cross-reactivity with other stromal cells and 20–40% of invasive carcinoma may show positivity
p-75	Good	Low	Cytoplasmic, membranous	Expressed in blood vessels, nerves and epithelial/luminal cells in usual epithelial hyperplasia and also expressed in 5% of invasive carcinomas
S100	Low	Low	Cytoplasmic, nuclear	May be positive in epithelial cells and invasive carcinomas
Other MEC markers				CD109, caveolin 1, podoplanin, nestin, alpha 1-integrin and 14-3-3 sigma (stratifin)
Basement membrane markers				
Laminin	Good	Good	Cytoplasmic	May be difficult to interpret due to background stromal staining but comparison with normal parenchyma may help
Collagen IV	Good	Good	Cytoplasmic	Similar to laminin

To demonstrate myoepithelial cells (MECs), a panel-based approach of two or more immunohistochemical markers is recommended. Many departments therefore use, for example, smooth muscle myosin (SMM) and p63 in order to avoid false negative results in differentiating *in situ* from invasive lesions. Aberrant expression of MEC markers is seen in salivary gland-like and skin adnexal-like tumours of the breast, adenomyoepithelioma and metaplastic mammary carcinomas.

epitheliosis there is no evidence of a thickened BM around areas lacking MECs.

A recent study has argued that infiltrating epitheliosis is neoplastic rather than hyperplastic, based on the frequent presence of *PIK3CA* mutations.[30] This study also identified shared clonal mutations in a case of infiltrating epitheliosis with synchronous micropapillary DCIS and adenosquamous carcinoma, again suggesting possible precursor status. Given that loss of MECs has been reported in approximately 20% of complex sclerosing lesions/radial scars, and these have a risk of breast cancer of only 1.5–2× above the general population, the frequency of such progression is likely to be rare (and currently unknown).

The inability to identify MECs using traditional markers in the context of complex sclerosing lesions may indicate phenotypical alterations in the MECs and a complex interaction between the proliferating

13652559, 2018, 7, Downloaded from https://onlinelibrary.wiley.com/doi/10.1111/his.13446 by George Mason University, Wiley Online Library on [10/03/2026]. See the Terms and Conditions (https://onlinelibrary.wiley.com/terms-and-conditions) on Wiley Online Library for rules of use; OA articles are governed by the applicable Creative Commons License

Table 2. Non-malignant conditions associated with lack of myoepithelial cells (MEC) and/or basement membrane (BM)

Lesion	MEC	BM	Infiltrative	Precursor to IBC	Risk of IBC
Microglandular adenosis	Absent	Present	Yes	Yes	Unknown
Infiltrating epitheliosis	Focally absent	Absent	Yes	Unknown	Rare
Radial scar/complex sclerosing lesion	Absent in 20%	Present	No	No	1.5–2×
Intraductal papilloma	Focally absent	Present	No	If epithelial atypia is present	2–3×
Infiltrative syringomatous tumour of the nipple	Absent	No	Yes	Unknown	Unknown
Fibroadenoma	Rarely absent	Present	No	No	No
Benign apocrine, including papillary foci	Absent	Present	No	No	No
Encapsulated apocrine papillary carcinoma	Absent	Present/pseudocapsule	No	Yes	Higher than DCIS
Encapsulated papillary carcinomas	Absent in 80%	Present/pseudocapsule	No	No	Higher than DCIS
Paget's disease	Absent	Absent	Yes	Yes	Unknown

IBC, Invasive breast cancer; DCIS, Ductal carcinoma *in situ*.

epithelial cells and MECs rather than their mechanical disappearance in such cases. In addition, a lack of MECs in epithelial displacement/seeding after needling procedures, such as fine-needle aspiration cytology, core biopsy or localisation/guidewire wire insertion, can be seen in association with both benign and malignant lesions and is not used as a criteria for the diagnosis of invasion, albeit that its clinical significance is somewhat unclear.[35]

Intraductal papilloma is a benign entity typically showing an intact layer of MECs at the epithelial–stroma interface.[36] However, a focal loss of MECs as demonstrated immunohistochemically can be seen, particularly in areas showing epithelial hyperplasia or when the proliferating epithelial cells show prominent apocrine differentiation.[37,38] Infiltrative syringomatous tumour of the nipple is another controversial benign lesion characterised by lack of peripheral MECs, together with an infiltrative growth pattern of glands and tubules mimicking tubular carcinoma or low-grade adenosquamous carcinoma.[39] However, in this setting IHC often highlights an outer layer of MECs around the tubules in this lesion, which could be interpreted as retention of MECs and hence the non-invasive nature of the lesion. Other rare examples of benign breast lesions featuring loss of peripheral MECs exist. We and others have observed this phenomenon in rare cases of fibroadenoma that lacked MECs focally at the epithelial–stroma interface.

Some apocrine lesions without MECs may be seen, as described by Cserni, who noted that lack of MECs in apocrine glands of the breast does not necessarily imply malignancy.[40] He described some benign apocrine papillary lesions of the breast lacking, or virtually lacking, MECs, a potential pitfall that should not be diagnosed as malignancy.[38] Five cases of encapsulated apocrine papillary carcinoma of the breast were described by Seal *et al.*,[41] with key histological features similar to those of classical encapsulated papillary carcinoma (EPC), including an absence of MECs both within the papillary structures and at the periphery. Cases were of pure apocrine appearance cytologically with variable degrees of atypia and mitotic activity. All lacked evidence of true invasion of tissue outside of the lesion and all had an indolent behaviour.

This collection of benign breast lesions indicates that the absence of MECs does not automatically indicate malignancy and/or invasion, but their absence is sometimes associated with an infiltrative growth pattern. This phenomenon may represent molecular changes in the proliferating epithelial cells that drive alteration, attenuation and/or atrophy, resulting in the disappearance of peripheral MECs of classical immunophenotype along with the appearance of focal infiltration of the adjacent stroma, but such changes are still not sufficient for designation as a fully malignant invasive phenotype.

Encapsulated papillary carcinoma lacks peripheral MECs in approximately 80% of cases, however; their behaviour is sufficiently indolent that it is widely considered as a lesion equivalent to *in-situ* disease.[42,43]

13652559, 2018, 7, Downloaded from https://onlinelibrary.wiley.com/doi/10.1111/his.13446 by George Mason University, Wiley Online Library on [10/03/2026]. See the Terms and Conditions (https://onlinelibrary.wiley.com/terms-and-conditions) on Wiley Online Library for rules of use; OA articles are governed by the applicable Creative Commons License

Pure EPC does not show a conventional infiltrative pattern of the stroma characteristic of IBC, indicating that the absence of MECs in these tumours *per se* does not drive the usual pattern of invasion seen in IBC. Solid papillary carcinoma (SPC) is another example of a malignant papillary lesion that may lack peripheral MECs, but behaves in an indolent fashion similar to DCIS.[44,45] Thus, the absence of MECs does not, by itself, imply that the lesion has acquired an invasive behaviour akin to conventional IBC, even if it has acquired the *in-situ* carcinoma characteristics of hyperproliferation and cellular atypia.[46]

Another exception to the role of peripheral MECs in preventing invasion in *in-situ* breast lesions (i.e. DCIS) is Paget's disease.[47] In Paget's disease, the malignant mammary epithelial cells escape their native environment and the confinement of the peripheral MECs and BM and infiltrate and populate the epidermis of the nipple adjacent to the involved mammary duct opening. Despite an absence of MECs and the native ducto-lobular BM, they remain confined to the epidermis and the majority do not invade the underlying dermis or stromal tissue. This pattern indicates that MECs and native BM of the ducto-lobular system are not the only barrier to invasion in DCIS, and implies that some as yet unknown tumour intrinsic factors are required for the progression from *in situ* to invasion. In addition, the surrounding stromal environment (stromal fibroblasts, immune cells and associated vasculature) could limit neoplastic cell spread.

Basement membrane and its role in the invasion process

The BM surrounding breast ducts is an essential barrier, formed mainly of collagen type IV and laminin 1 along with some proteoglycans.[48] This layer is deposited by epithelial, myoepithelial and stromal cells and plays key roles in homeostasis of normal architecture and physiology.[48,49] It must be remembered and emphasised that the fundamental and original definition of invasive carcinoma is based upon penetration through the BM and establishment of growth within the stroma, and not loss of MECs.[50] Therefore, is the BM a rate-limiting barrier for invasion? BMs are conceived to form a protective hurdle against primary infiltration of the surrounding stroma by malignant epithelial cells, and invasion of the BM has been reported as sufficient for breast cancer cells to develop a stable metastatic phenotype.[51]

Although focal disruptions in the MEC layer can be observed in DCIS, the surrounding BM is typically intact and continuous and can be used to indicate the *in-situ* nature of the lesion.[9] However, in the clinical setting it is often not simple; differentiating native BM surrounding the ducto-lobular system from reactive BM around some invasive lesions may be problematic. EPC shows a peripheral thick capsule/thickened BM-like structure which was interpreted as an evidence of the *in-situ* nature of these tumours.[52] However, a similar capsule/BM-like structure can be seen in other structures outside the breast, suggesting that this is a reactive process rather than an expansion of the surrounding native BM material.[53] Conversely, BM-like structures have also been observed around invasive tumours even at distant metastatic sites,[54–56] and may be particularly conspicuous in some special variants of invasive carcinoma, such as adenoid cystic carcinoma. Other invasive lesions, such as squamous cell carcinoma, show BM surrounding the invasive tumour nests.[57] Finally, some breast carcinomas show DCIS-like structures in the lymph nodes (revertant DCIS[58]), typically surrounded by BM-like material. BM-like structures are also present in benign lesions such as collagenous spherulosis. In these the material has been found histochemically and immunohistochemically to be BM-like, consisting of type IV collagen.[59]

Overall, these findings raise questions in breast histopathology about what definition of invasion can be used reliably in routine practice, taking into account the significant management implications of *in-situ* versus invasive diagnosis. Given the subjective nature of interpretation of BM material staining, a panel of MEC markers is regarded as the gold standard for assessment of invasion in breast pathology. However, while the presence of MECs, as shown by IHC, has an excellent negative predictive value for invasion, their absence does not always indicate invasive (and thus metastatic) capacity of a lesion.

In conclusion, the role of MECs and the BM in tumour progression is under-recognised. However, much remains to be clarified about the molecular mechanisms and physiological roles of MECs in tumour invasion and metastasis. Further research may lead to the development of novel approaches for the prevention and treatment of breast cancer. This is of particular relevance for pre-invasive breast lesions such as DCIS, where MECs and BM may conceivably be useful targets for the prevention of invasive disease. At the present time, however, pathologists should be aware of the pitfalls of criteria used in routine practice to distinguish *in-situ* from invasive disease. Although it is convenient, and often useful, to use identification of loss of MECs by IHC as a

13652559, 2018, 7, Downloaded from https://onlinelibrary.wiley.com/doi/10.1111/his.13446 by George Mason University, Wiley Online Library on [10/03/2026]. See the Terms and Conditions (https://onlinelibrary.wiley.com/terms-and-conditions) on Wiley Online Library for rules of use; OA articles are governed by the applicable Creative Commons License

surrogate marker of invasion it must be remembered that such observations do not indicate *per se* that the BM has been breached and this alone remains the key definition of, and requirement for, invasion. We advise caution in interpretation of MEC features in breast pathology, and mindfulness of the substantive evidence base in the literature associated with behaviour and clinical outcome of lesions classified as benign on conventional morphological examination before changing classification of a lesion to an invasive on the sole basis of MEC characteristics.

References

1. Lippman M. Why study ductal carcinoma *in situ*? In Silverstein MJ, Recht A, Lagios M eds. *Ductal carcinoma in situ of the breast*. 2nd edn. Philadelphis, PA: Lippincott: Williams and Wilkins, 2002; 12–16.
2. Lopez-Garcia MA, Geyer FC, Lacroix-Triki M, Marchio C, Reis-Filho JS. Breast cancer precursors revisited: molecular features and progression pathways. *Histopathology* 2010; **57**; 171–192.
3. Allred DC, Wu Y, Mao S *et al.* Ductal carcinoma in situ and the emergence of diversity during breast cancer evolution. *Clin. Cancer Res.* 2008; **14**; 370–378.
4. Hu M, Yao J, Carroll DK *et al.* Regulation of *in situ* to invasive breast carcinoma transition. *Cancer Cell* 2008; **13**; 394–406.
5. Gudjonsson T, Adriance MC, Sternlicht MD, Petersen OW, Bissell MJ. Myoepithelial cells: their origin and function in breast morphogenesis and neoplasia. *J. Mammary Gland Biol. Neoplasia* 2005; **10**; 261–272.
6. Barsky SH, Karlin NJ. Myoepithelial cells: autocrine and paracrine suppressors of breast cancer progression. *J. Mammary Gland Biol. Neoplasia* 2005; **10**; 249–260.
7. Pang JB, Savas P, Fellowes AP *et al.* Breast ductal carcinoma *in situ* carry mutational driver events representative of invasive breast cancer. *Mod. Pathol.* 2017; **30**; 952–963.
8. Man YG, Shen T, Weisz J *et al.* A subset of *in situ* breast tumor cell clusters lacks expression of proliferation and progression related markers but shows signs of stromal and vascular invasion. *Cancer Detect. Prev.* 2005; **29**; 323–331.
9. Man YG, Tai L, Barner R *et al.* Cell clusters overlying focally disrupted mammary myoepithelial cell layers and adjacent cells within the same duct display different immunohistochemical and genetic features: implications for tumor progression and invasion. *Breast Cancer Res.* 2003; **5**; R231–R241.
10. Coussens LM, Fingleton B, Matrisian LM. Matrix metalloproteinase inhibitors and cancer: trials and tribulations. *Science* 2002; **295**; 2387–2392.
11. Man YG, Sang QX. The significance of focal myoepithelial cell layer disruptions in human breast tumor invasion: a paradigm shift from the 'protease-centered' hypothesis. *Exp. Cell Res.* 2004; **301**; 103–118.
12. Gudjonsson T, Ronnov-Jessen L, Villadsen R, Rank F, Bissell MJ, Petersen OW. Normal and tumor-derived myoepithelial cells differ in their ability to interact with luminal breast epithelial cells for polarity and basement membrane deposition. *J. Cell Sci.* 2002; **115**; 39–50.
13. Dey P. Epigenetic changes in tumor microenvironment. *Ind. J. Cancer* 2011; **48**; 507–512.
14. Polyak K, Hu M. Do myoepithelial cells hold the key for breast tumor progression? *J. Mammary Gland Biol. Neoplasia* 2005; **10**; 231–247.
15. Rohilla M, Bal A, Singh G, Joshi K. Phenotypic and functional characterization of ductal carcinoma *in situ*-associated myoepithelial cells. *Clin. Breast Cancer* 2015; **15**; 335–342.
16. Sternlicht MD, Kedeshian P, Shao ZM, Safarians S, Barsky SH. The human myoepithelial cell is a natural tumor suppressor. *Clin. Cancer Res.* 1997; **3**; 1949–1958.
17. Adriance MC, Inman JL, Petersen OW, Bissell MJ. Myoepithelial cells: good fences make good neighbors. *Breast Cancer Res.* 2005; **7**; 190–197.
18. Koukoulis GK, Virtanen I, Korhonen M, Laitinen L, Quaranta V, Gould VE. Immunohistochemical localization of integrins in the normal, hyperplastic, and neoplastic breast. Correlations with their functions as receptors and cell adhesion molecules. *Am. J. Pathol.* 1991; **139**; 787–799.
19. Hu M, Yao J, Cai L *et al.* Distinct epigenetic changes in the stromal cells of breast cancers. *Nat. Genet.* 2005; **37**; 899–905.
20. Allinen M, Beroukhim R, Cai L *et al.* Molecular characterization of the tumor microenvironment in breast cancer. *Cancer Cell* 2004; **6**; 17–32.
21. Hilson JB, Schnitt SJ, Collins LC. Phenotypic alterations in ductal carcinoma in situ-associated myoepithelial cells: biologic and diagnostic implications. *Am. J. Surg. Pathol.* 2009; **33**; 227–232.
22. Chivukula M, Domfeh A, Carter G, Tseng G, Dabbs DJ. Characterization of high-grade ductal carcinoma *in situ* with and without regressive changes: diagnostic and biologic implications. *Appl. Immunohistochem. Mol. Morphol.* 2009; **17**; 495–499.
23. Peyrol S, Raccurt M, Gerard F, Gleyzal C, Grimaud JA, Sommer P. Lysyl oxidase gene expression in the stromal reaction to *in situ* and invasive ductal breast carcinoma. *Am. J. Pathol.* 1997; **150**; 497–507.
24. Stephenson JM, Banerjee S, Saxena NK, Cherian R, Banerjee SK. Neuropilin-1 is differentially expressed in myoepithelial cells and vascular smooth muscle cells in preneoplastic and neoplastic human breast: a possible marker for the progression of breast cancer. *Int. J. Cancer* 2002; **101**; 409–414.
25. Machowska M, Wachowicz K, Sopel M, Rzepecki R. Nuclear location of tumor suppressor protein maspin inhibits proliferation of breast cancer cells without affecting proliferation of normal epithelial cells. *BMC Cancer* 2014; **14**; 142.
26. Allen MD, Marshall JF, Jones JL. αvβ6 Expression in myoepithelial cells: a novel marker for predicting DCIS progression with therapeutic potential. *Cancer Res.* 2014; **74**; 5942–5947.
27. Wen YH, Weigelt B, Reis-Filho JS. Microglandular adenosis: a non-obligate precursor of triple-negative breast cancer? *Histol. Histopathol.* 2013; **28**; 1099–1108.
28. Shui RH, Cheng YF, Yang WT. [Invasive carcinoma arising in breast microglandular adenosis: a clinicopathologic study of three cases and review of the literature]. *Zhonghua Bing Li Xue Za Zhi* 2011; **40**; 471–474.
29. Yamaguchi R, Maeshiro K, Ellis IO *et al.* Infiltrative epitheliosis of the breast. *J. Clin. Pathol.* 2012; **65**; 766–768.
30. Eberle CA, Piscuoglio S, Rakha EA *et al.* Infiltrating epitheliosis of the breast: characterization of histologic features, immunophenotype and genomic profile. *Histopathology* 2016; **68**; 1030–1039.
31. Geyer FC, Berman SH, Marchio C *et al.* Genetic analysis of microglandular adenosis and acinic cell carcinomas of the breast

13652559, 2018, 7, Downloaded from https://onlinelibrary.wiley.com/doi/10.1111/his.13446 by George Mason University, Wiley Online Library on [10/03/2026]. See the Terms and Conditions (https://onlinelibrary.wiley.com/terms-and-conditions) on Wiley Online Library for rules of use; OA articles are governed by the applicable Creative Commons License

provides evidence for the existence of a low-grade triple-negative breast neoplasia family. *Mod. Pathol.* 2017; **30**; 69–84.
32. Shin SJ, Simpson PT, Da Silva L *et al.* Molecular evidence for progression of microglandular adenosis (MGA) to invasive carcinoma. *Am. J. Surg. Pathol.* 2009; **33**; 496–504.
33. Azzopardi JG, Ahmed A, Millis RR. Problems in breast pathology. *Major Prob. Pathol.* 1979; **11**; i–xvi, 1–466.
34. Rosen PP. Papilloma and related benign tumors. In Rose PP ed. *Rosen's breast pathology*. 3rd edn. Philadelphia, PA: Lippincott-Williams & Wilkins, 2009; 85e186.
35. Phelan S, O'Doherty A, Hill A, Quinn CM. Epithelial displacement during breast needle core biopsy causes diagnostic difficulties in subsequent surgical excision specimens. *J. Clin. Pathol.* 2007; **60**; 373–376.
36. Basavaiah SH, Minal J, Sreeram S *et al.* Diagnostic pitfalls in papillary lesions of the breast: experience from a single tertiary care center. *J. Clin. Diagn. Res.* 2016; **10**; Ec18–Ec21.
37. Hayashi H, Ohtani H, Yamaguchi J, Shimokawa I. A case of intracystic apocrine papillary tumor: diagnostic pitfalls for malignancy. *Pathol. Res. Pract.* 2013; **209**; 808–811.
38. Cserni G. Benign apocrine papillary lesions of the breast lacking or virtually lacking myoepithelial cells – potential pitfalls in diagnosing malignancy. *APMIS* 2012; **120**; 249–252.
39. Oo KZ, Xiao PQ. Infiltrating syringomatous adenoma of the nipple: clinical presentation and literature review. *Arch. Pathol. Lab. Med.* 2009; **133**; 1487–1489.
40. Cserni G. Lack of myoepithelium in apocrine glands of the breast does not necessarily imply malignancy. *Histopathology* 2008; **52**; 253–255.
41. Seal M, Wilson C, Naus GJ, Chia S, Bainbridge TC, Hayes MM. Encapsulated apocrine papillary carcinoma of the breast – a tumour of uncertain malignant potential: report of five cases. *Virchows Arch.* 2009; **455**; 477–483.
42. Tariq N, Mamoon N, Usman M, Ali Z, Nazir I. Encapsulated papillary carcinoma (EPC) of breast: a clinical, pathological and immunohistochemical analysis of eight cases. *J. Pakistan Med. Assoc.* 2016; **66**; 1490–1493.
43. Tavassoli T, Devilee P. *Pathology & genetics. Tumours of the breast and female genital organs*. Lyon, France: IARC Press, 2003.
44. Tan BY, Thike AA, Ellis IO, Tan PH. Clinicopathologic characteristics of solid papillary carcinoma of the breast. *Am. J. Surg. Pathol.* 2016; **40**; 1334–1342.
45. Tan PH, Schnitt SJ, van de Vijver MJ, Ellis IO, Lakhani SR. Papillary and neuroendocrine breast lesions: the WHO stance. *Histopathology* 2015; **66**; 761–770.
46. Nassar H, Qureshi H, Adsay NV, Visscher D. Clinicopathologic analysis of solid papillary carcinoma of the breast and associated invasive carcinomas. *Am. J. Surg. Pathol.* 2006; **30**; 501–507.
47. Sanders M, Lester S. Paget disease of the breast with invasion from nipple skin into the dermis. *Arch. Pathol. Lab. Med.* 2013; **137**; 307.
48. LeBleu VS, Macdonald B, Kalluri R. Structure and function of basement membranes. *Exp. Biol. Med.* 2007; **232**; 1121–1129.
49. Halfter W, Oertle P, Monnier CA *et al.* New concepts in basement membrane biology. *FEBS J.* 2015; **282**; 4466–4479.
50. Lester S. *Robbins and Cotran pathologic basis of disease*. 8th edn. Philadelphia, PA: Saunders Elsevier, 2010.
51. Abdelkarim M, Vintonenko N, Starzec A *et al.* Invading basement membrane matrix is sufficient for MDA-MB-231 breast cancer cells to develop a stable *in vivo* metastatic phenotype. *PLoS ONE* 2011; **6**; e23334.
52. Wynveen CA, Nehhozina T, Akram M *et al.* Intracystic papillary carcinoma of the breast: an *in situ* or invasive tumor? Results of immunohistochemical analysis and clinical follow-up. *Am. J. Surg. Pathol.* 2011; **35**; 1–14.
53. Rakha EA, Gandhi N, Climent F *et al.* Encapsulated papillary carcinoma of the breast: an invasive tumor with excellent prognosis. *Am. J. Surg. Pathol.* 2011; **35**; 1093–1103.
54. Albrechtsen R, Nielsen M, Wewer U, Engvall E, Ruoslahti E. Basement membrane changes in breast cancer detected by immunohistochemical staining for laminin. *Cancer Res.* 1981; **41**; 5076–5081.
55. Saremian J, Rosa M. Solid papillary carcinoma of the breast: a pathologically and clinically distinct breast tumor. *Arch. Pathol. Lab. Med.* 2012; **136**; 1308–1311.
56. Visscher DW, Sarkar FH, Sakr W, Crissman J. Immunohistologic analysis of invasive phenotype in breast carcinoma. A clinicopathologic study. *Pathol. Res. Pract.* 1993; **189**; 867–872.
57. Gusterson BA, Warburton MJ, Mitchell D, Kraft N, Hancock WW. Invading squamous cell carcinoma can retain a basal lamina. An immunohistochemical study using a monoclonal antibody to type IV collagen. *Lab. Invest.* 1984; **51**; 82–87.
58. Barsky SH, Doberneck SA, Sternlicht MD, Grossman DA, Love SM. 'Revertant' DCIS in human axillary breast carcinoma metastases. *J. Pathol.* 1997; **183**; 188–194.
59. Highland KE, Finley JL, Neill JS, Silverman JF. Collagenous spherulosis. Report of a case with diagnosis by fine needle aspiration biopsy with immunocytochemical and ultrastructural observations. *Acta Cytol.* 1993; **37**; 3–9.

13652559, 2018, 7, Downloaded from https://onlinelibrary.wiley.com/doi/10.1111/his.13446 by George Mason University, Wiley Online Library on [10/03/2026]. See the Terms and Conditions (https://onlinelibrary.wiley.com/terms-and-conditions) on Wiley Online Library for rules of use; OA articles are governed by the applicable Creative Commons License